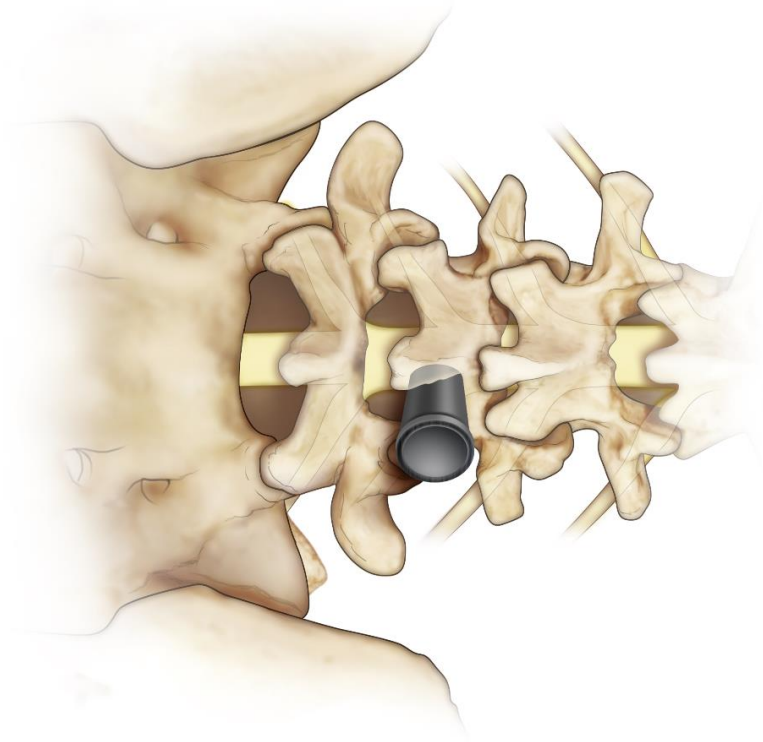




Dr Sai Viksheth Raj B

SPINE AND SCOLIOSIS SPECIALIST

**Microsurgical Treatment of Spinal Disorders
through Minimally Invasive Tubular Retractors**



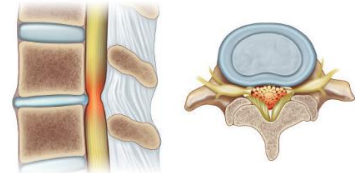
Understanding the Spine

The spine is made up of vertebrae, which are bones that are stacked on top of each other in a column. Between these bones are discs that act as cushions. The discs have a tough outer ring called the annulus fibrosus. This outer layer covers the inner gel-like center of the disc, called the nucleus pulposus. The vertebrae meet at bony junctions called facet joints connected by ligaments called ligamentum flavum. The spinal cord and nerves are contained in the spinal canal, which runs through the column made by the vertebrae. Nerves exit the spinal canal on each side through the foramina, which are openings between the vertebrae.

Common Low Back Issues

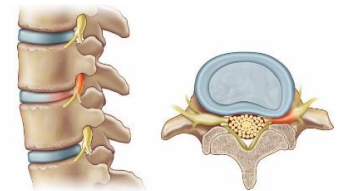
Spinal Canal Stenosis (Narrowing)

- Usually develops slowly over years
- May be caused by disc breakdown, disc herniation, osteoarthritis, bone spurs, thickening of the ligaments (ligamentum flavum)
- Narrowing of the spinal canal may cause pressure on the nerves which can cause low back pain with possible leg pain, numbness, or weakness



Foraminal Stenosis

- Narrowing of the openings between vertebrae where the spinal nerves exit the spinal column
- May be caused by bone spurs (outgrowth of bone), herniated or bulging discs
- Foraminal narrowing may lead to trapping or constriction of the nerves which can cause low back pain, hip pain, buttock pain, leg pain, numbness, weakness, or cramping – symptoms are often only on one side of the body



Synovial Cyst

- A synovial cyst is a fluid-filled sac that comes off of the facet joint
- The cyst can grow large enough to cause pressure on the nerves which can cause low back pain and/or leg pain, numbness, or weakness

Disc Herniation

- As the body ages, disc height can become reduced, which can lead to “rupture” or “herniation” of the inner gel-like disc (nucleus pulposus)
- This herniation may bulge into the spinal canal, causing pressure on the nerve which may cause sudden back pain, numbness/tingling in the buttocks or legs, searing pain down one or both legs

Treatment Options:

Conservative Treatment Options

All of these common low back issues may first be treated with conservative management. This may include rest, weight reduction, medication, physical therapy, and/or steroid injections.

Surgical Options

Surgery is usually saved as the last treatment option for those who have not had improvement of symptoms with conservative treatments. Surgery often involves direct decompression, where the pressure is removed from the nerve, which may include laminectomy, foraminotomy, and/or discectomy. These surgeries can be done via traditional open approach, which may disturb structures and cause or worsen instability.

The alternative approach is a **minimally invasive approach (MIS)**. This method of minimally invasive technique avoids separation of muscles and preserves stabilizing structures. Compared to open approaches, MIS decompression may result in less post-operative instability of the spine.

How is MIS decompression better?

The surgical outcome and relief of symptoms with MIS is similar to a traditional open procedure. However, since tubular retractors allow surgeons to decompress nerves through a small tube, it offers several advantages:

- A Small Incision
- Less Muscle Damage – retractor tools spread the muscle instead of stripping or cutting it from the bone, which decreases post-operative pain and allow for an easier recovery
- Less Post-Operative Pain
- Shorter Hospitalization and Speedier Recovery – may even be done as an outpatient
- High Patient Satisfaction Scores

Another Key Benefit

Traditionally, patients with lumbar spinal stenosis and pre-existing *spondylolisthesis* (slippage of the vertebrae on each other) are treated by open decompressive surgery and additional fusion to ensure no worsening instability.

Recently, it was noted that MIS laminectomy is associated with a lower post-operative instability rate when compared to open decompressive surgery. The study suggested that routine fusion may *not* be indicated in all patients with lumbar spinal stenosis and spondylolisthesis.

The Procedure

Tubular retractors are tools that create tunnels through which the spine can be accessed. The muscles are not scraped away from the bones of the spine, but stay attached to it. A microscope is used to look through the small tubular retractor to visualize compressed neural elements. They are then decompressed using special microsurgical instruments.

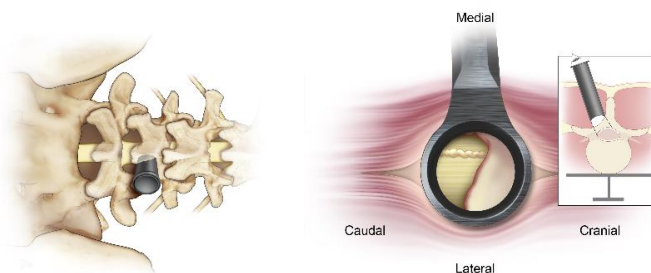
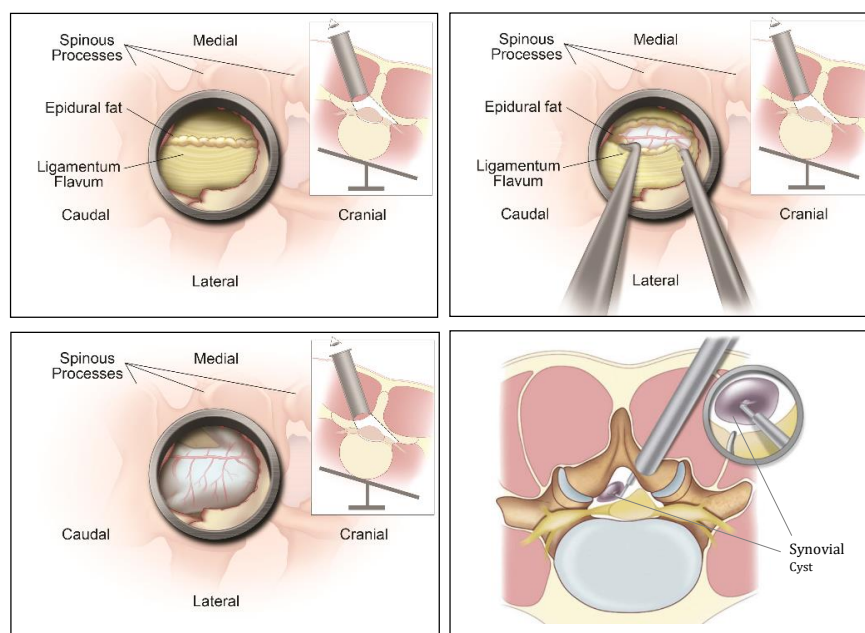


Figure 1: Stages of Minimally Invasive (MIS) decompressive procedure using tubular retractors



The Results and Scientific Evidence

- Our previous study of 230 patients who had a microsurgical decompression showed that the procedure was a *safe* and *highly effective* treatment alternative with similar clinical outcomes as open surgery, while having the advantages of MIS surgery.¹
- In another study of 110 patients with lumbar spinal stenosis who had a laminectomy using tubular retractors, patients were followed up for an average of 28 months. The results showed that the procedure was *effective* and yielded *favorable outcome* and *high satisfaction rate*.
- It also showed that fusion may not be indicated in all patients with LSS and spondylolisthesis.²
- Benefits of tubular retractors are not only limited to laminectomy. They have also been successfully applied to foraminotomy and discectomy procedures.^{1,3}

References:

1. Parikh K, Tomasino A, Knopman J, Boockvar J, Hartl R. Operative results and learning curve: microscope-assisted tubular microsurgery for 1- and 2-level discectomies and laminectomies. *Neurosurg Focus*. 2008;25(2):E14.
2. Alimi M, Hofstetter CP, Pyo SY, Paulo D, Härtl R. Minimally invasive laminectomy for lumbar spinal stenosis in patients with and without pre-operative spondylolisthesis: clinical outcome and re-operation rates. *J Neurosurgery Spine*. 2014;Accepted.
3. Alimi M, Njoku I, Jr., Cong GT, et al. Minimally invasive foraminotomy through tubular retractors via a contralateral approach in patients with unilateral radiculopathy. *Neurosurgery*. Sep 2014;10 Spinal 3:436-447: discussion 446-437.